

FIRST YEAR CASES

Prepared by

DR SHUZAN ALI MOHAMMED

Case 1

A 20 years old patient was ambulated to the hospital in coma. The respiratory rate was slow. He was put on a ventilator. Lab investigations for his blood sample revealed presence of morphia and the blood pH was 7.1.

Questions

1. The suggested acid base imbalance in this case is:
 - a. Respiratory alkalosis
 - b. Metabolic alkalosis
 - c. Respiratory acidosis
 - d. Metabolic acidosis

2. All the following apply to this case except:

a. Excessive CO₂ retention

b. Respiratory center depression

c. Normal alkali reserve

d. Increased HCO₃⁻ / H₂CO₃

- 3. The body compensates for this case by:**
- a. increasing respiratory rate**
 - b. excreting more HCO_3^-**
 - c. reabsorbing more HCO_3^-**
 - d. decreasing respiratory rate**



Case 2


A diabetic patient does not receive her treatment in a regular manner. Laboratory data of the patient showed high blood glucose, blood pH was 7.2 and her urine sample was (+++) for both glucose and acetone. Her main complaint was frequent micturation.

Questions

1. The suggested acid base imbalance in this case is:

- a. Respiratory alkalosis**
- b. Metabolic alkalosis**
- c. Respiratory acidosis**
- d. Metabolic acidosis**

2. The mechanism of acid base imbalance in this case is:

- a. Administration NH_4Cl**
 - b. Excess ketone bodies**
 - c. Excess citrate salts**
 - d. None of the above**
- 

3. The following is increased in this condition:

a. Citrate

b. Acetoacetate


c. β -hydroxybutarate

d. b and c

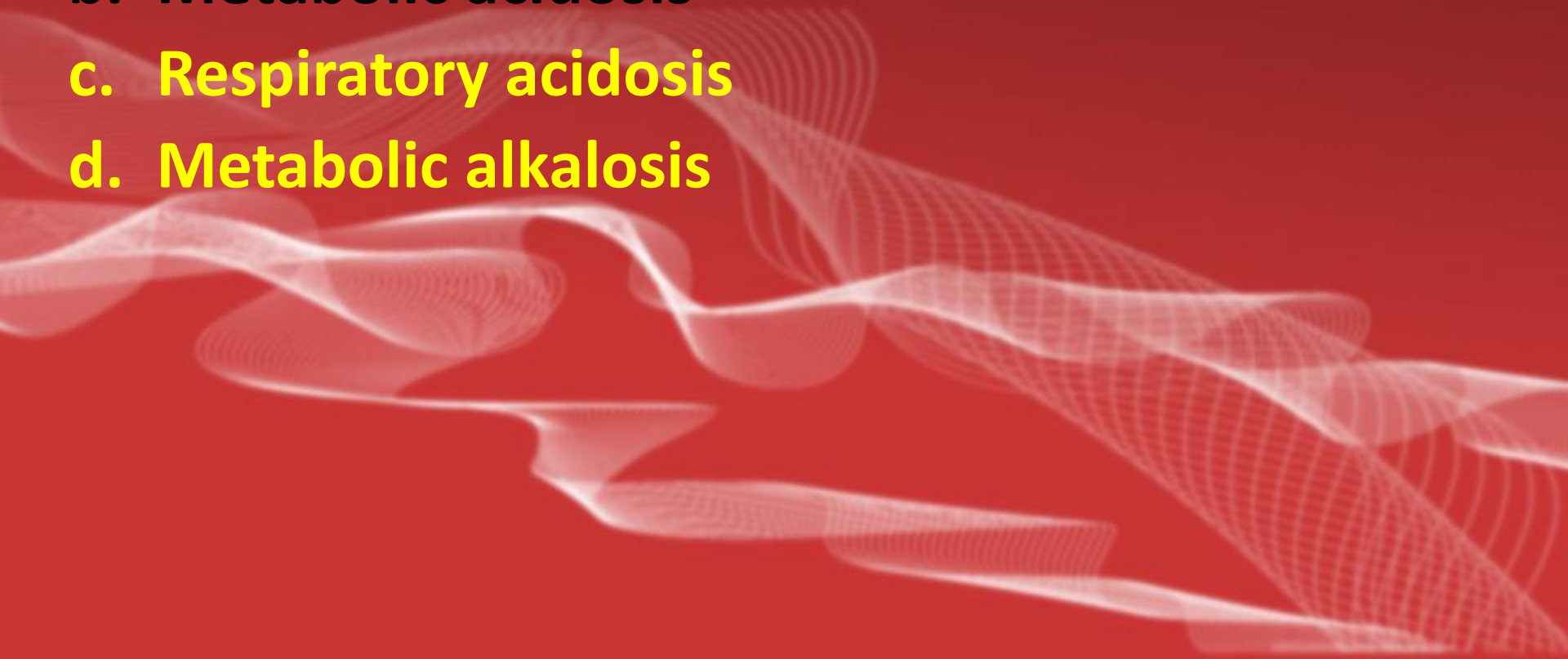


Case 3

A child got severe diarrhea, after few hours he lost conscious and his mother took him to the hospital. The physician asked for some lab investigations and gave him intravenous fluids.

The background of the slide features a solid red color. In the lower half, there are several overlapping, wavy, white lines that create a sense of motion and depth, resembling a stylized wave or a digital signal pattern.

Questions

1. The suggested acid base imbalance in this case is:
 - a. Respiratory alkalosis
 - b. Metabolic acidosis
 - c. Respiratory acidosis
 - d. Metabolic alkalosis
- 

2. The mechanism of acid base imbalance in this case is:

- a. Loss of Na^+ and K^+ bicarbonate
- b. Hyperkalemia
- c. Failure to excrete acids
- d. Increased H_2CO_3

3. The body can compensate pH of this case by:

a. Inhibition of respiration

b. Stimulation of respiration

c. Increased excretion of HCO_3^-

d. None of the above



Case 4

A patient with chronic renal failure was hospitalized due to the presence of severe oedema in both limbs and enlarged abdomen due to fluid accumulation (ascitis). His laboratory data showed impaired renal function tests and decreased serum albumin level.

Questions

1. The suggested acid base imbalance in this case is:
 - a. Respiratory alkalosis
 - b. Metabolic acidosis
 - c. Respiratory acidosis
 - d. Metabolic alkalosis

2. The acid base imbalance in this case is due to accumulation of the following, except:

- a. Fatty acids**
- b. Uric acid**
- c. Phosphoric acid**
- d. Carbonic acid**

Case 5

A female patient suffers chronic peptic ulcer. She is on regular antacid treatment. She get worse and admitted to the hospital to be investigated; her blood pH was 7.55.

Questions

1. The suggested acid base imbalance in this case is:
 - a. Respiratory alkalosis
 - b. Metabolic acidosis
 - c. Respiratory acidosis
 - d. Metabolic alkalosis

2. The acid base imbalance in this case is due to the increase in:

a. Fatty acids

b. Urate

c. Bicarbonate

d. Carbonic acid

3- The compensation of this acid-base imbalance is by:

a. Respiratory inhibition

b. Respiratory stimulation

c. Inhibition of bicarbonate reabsorption

d. Intravenous bicarbonate injection

4- the alkaline reserve in this case is:

a. Low

b. High

c. Normal

d. Non of the above

Case 6

1- In hyperkalemia; all the following conditions apply, except:

- a. Renal $\text{Na}^+ : \text{K}^+$ exchange acts.
- b. Absent renal $\text{Na}^+ : \text{H}^+$ exchange.
- c. Hypochloraemic acidosis
- d. paradoxical acidosis.

